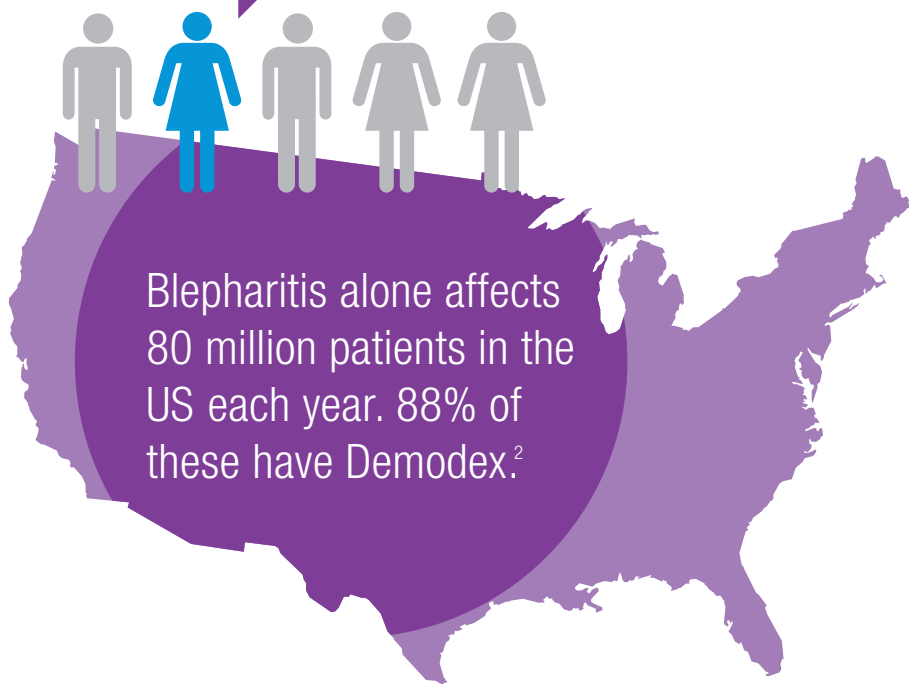


# Achieve Optimal Ocular Hygiene with Cliradex® for the Eyelids, Lash and the Face

Ocular Surface Disease accounts for one in five visits to eye care practitioners<sup>1</sup>



- ✓ An Ideal Lid Margin Cleaner
- ✓ A Killer of Demodex Mites
- ✓ Anti-Fungal
- ✓ Anti-Microbial
- ✓ Anti-Inflammatory
- ✓ The Isolated Active Ingredient From All Natural Tea Tree Oil



Start treating the causes of OSD.  
Ask Your Doctor if Cliradex is Right for You or Simply Visit [Cliradex.com](http://Cliradex.com) to Order or for More Information.\*

Cliradex Towelettes for Everyday Home Use.



THE ESSENTIAL, ALL NATURAL & EFFECTIVE WAY TO CLEAN LASHES, EYELIDS AND FACE.

Contact BioTissue for more information or for sample requests.

BioTissue, 8305 NW 27th Street, Suite 101, Doral, FL 33122  
biotissue.com 1-888-296-8858



## Common Causes of OSD

### Blepharitis

Blepharitis is a common eyelid inflammation that is sometimes associated with a bacterial eye infection, symptoms of dry eye, and skin conditions such as acne and rosacea.<sup>3</sup> Blepharitis symptoms include: more frequent blinking, red, watery eyes, itching, loss of eyelashes, burning, stinging, and greasy appearance.




### Demodex Mites

Demodex Blepharitis is the most common but overlooked external disease problem, causing ocular surface inflammation and can exacerbate many pre-existing ocular surface conditions like dry eye and pterygium.




### Meibomian Gland Dysfunction

Meibomian gland dysfunction (MGD) is a chronic disease, usually caused by obstruction of the secretory Meibomian glands. The subsequent reduction of gland secretion results in a decreased amount of lipids in the tear film. This results in a faster evaporation of the tear film and thus an evaporative dry eye. MGD alone is responsible for about 60% of all cases in combination with aqueous deficiency for a further 20% of dry eyes.<sup>4</sup>



### Rosacea

Rosacea is a common skin disease. It often begins with a tendency to blush or flush more easily than other people. Ocular rosacea presents red and irritated eyes, eyelids can be swollen, and person may have what looks like a sty.<sup>5</sup>



### Chalazia

A chalazion is a slowly developing lump that forms due to blockage and swelling of an oil gland in the eyelid. It is more common in adults than children and occurs most frequently in persons 30 to 50 years of age. Initially, a chalazion may appear as a red, tender, swollen area of the eyelid.



1. American Optometric Association Clinical Practice Survey 2011 2. Bhandari V, Reddy JK, Blepharitis: always remember demodex., Middle East Afr J Ophthalmol. 2014 Oct-Dec;21(4):317-20. 3. <http://www.allaboutvision.com/conditions/blepharitis.htm> 4. <http://www.ncbi.nlm.nih.gov/pubmed/22592341> 5. <https://www.aad.org/dermatology-a-to-z/diseases-and-treatments/q---t/rosacea>